


# Comparison of Ultrasound-guided Hernia Block with Standard Subarachnoid Block: An Open Label Randomised Clinical Study

DINESH KUMAR SAHU<sup>1</sup>, DAR M FAIZANA<sup>2</sup>, SONAWANE ALPA<sup>3</sup>, ATUL SHARMA<sup>4</sup>

## ABSTRACT

**Introduction:** Inguinal hernia surgery is preferably performed under Subarachnoid Block (SAB) or General Anaesthesia (GA). However, some patients may have contraindications for both types of anaesthesia. An Ilioinguinal-Iliohypogastric Nerve (IIN-IHN) block can be administered for inguinal hernia surgery, but sometimes it provides unsatisfactory anaesthesia, and combining it with the genital branch of the genitofemoral nerve is suggested. The use of ultrasound is recommended to increase efficacy and reduce adverse effects of the block.

**Aim:** To compare the intraoperative anaesthetic efficacy of ultrasound-guided ilioinguinal, iliohypogastric, and genitofemoral nerve blocks, collectively referred to as Hernia Block (HB), with SAB in patients undergoing elective unilateral uncomplicated open indirect inguinal hernia repair.

**Materials and Methods:** An open-label randomised clinical study was designed to include 40 adults aged 18 to 80 years, classified as American Society of Anaesthesiologists (ASA) class I-III, undergoing elective open surgery for indirect inguinal hernia. Patients were randomised into two groups: Group A received SAB, while group B received ultrasound-guided HB only. A comparison was made between both groups in terms of intraoperative anaesthetic efficacy, success rate, duration of analgesia, haemodynamic changes, complications, time to ambulation, patient satisfaction, surgeon satisfaction, and adverse effects. Statistical analysis was

performed using Analysis of Variance, Student's t-test, and the Mann-Whitney test.

**Results:** The median age (range) of group A was 56 (33-68) years, while that of group B was 50 (26-76) years. Mean arterial pressure showed a statistically significant reduction between 30 to 90 minutes in group A patients (p-value <0.05). The median time taken to perform the block was significantly shorter in group A, at 11 (5-22) minutes, compared to 41 (27-70) minutes in group B (p-value of 0.002). The median time to onset of surgical anaesthesia was significantly shorter in group A, at 5 (3-10) minutes, compared to 30 (15-75) minutes in group B (p-value=0.003). The duration of analgesia was significantly longer in group B, at 8 (2-11) hours, compared to 5 (3-7) hours in group A (p-value=0.002). The success rate in the ultrasound-guided HB group was 80%, while it was 100% in the SAB group (p-value=0.05). Adverse events related to the procedure were significantly higher in the SAB group (55% vs 10%, p-value=0.003). Both surgeon and patient satisfaction were significantly better in SAB group. The median ambulation time was significantly faster in the ultrasound group, at 5.5 hours, compared to 11.5 hours in the SAB group.

**Conclusion:** The ultrasound-guided HB may be considered an effective alternative with an acceptable success rate to SAB for unilateral indirect inguinal hernia repair, particularly in terms of haemodynamic stability, postoperative analgesia, fewer complications, and early ambulation.

**Keywords:** Genital branch of genitofemoral nerve, Hernia block, Iliohypogastric, Ilioinguinal, Inguinal, Ultrasound

## INTRODUCTION

Inguinal hernia is the most common type of hernia across different age groups [1]. The consensus regarding the choice of anaesthesia for inguinal hernia surgery varies based on patient condition and surgeon preference [2]. Studies have shown that GA and central neuraxial blockade are the preferred choices of anaesthesia in the majority of cases, with less preference given to regional and local anaesthesia for hernia operations [3,4]. The IIN-IHN block can be administered for inguinal hernia surgery; however, it sometimes provides unsatisfactory anaesthesia, and combining it with the genital branch of the genitofemoral nerve is suggested [5,6]. The use of ultrasound guidance to perform an IIN-IHN block has been associated with improved perioperative analgesia in patients following open inguinal surgery compared to landmark-based methods [7]. Ultrasound-guided nerve block may be an ideal technique, as it produces the least physiological disturbance and helps increase the success rate while avoiding complications associated with the blind approach of conventional techniques [8-10].

There are few studies that include ultrasound guidance and the combination of the genital branch of the genitofemoral nerve with the IIN-IHN block [9-12]. Hence, a randomised study was conducted to compare the intraoperative anaesthetic efficacy of ultrasound-guided IIN-IHN block combined with genitofemoral nerve block to

SAB in patients undergoing elective unilateral open inguinal hernia repair in adults.

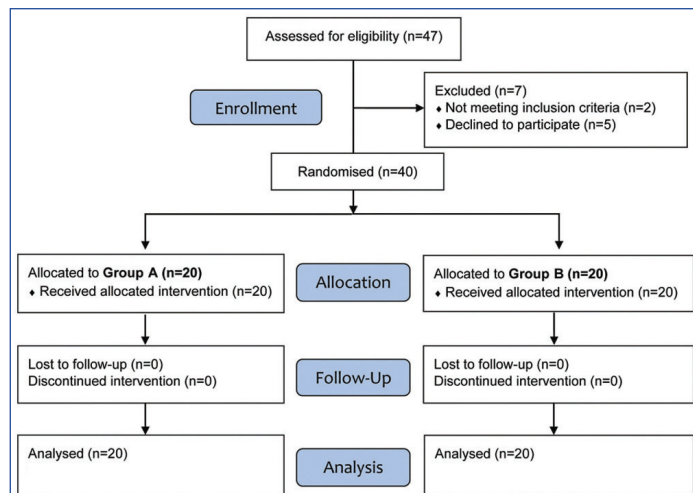
## MATERIALS AND METHODS

A prospective randomised open-label study was conducted in the Department of Anaesthesiology at Jagjivan Ram Railway Hospital, Mumbai, Maharashtra, India from September 2019 to September 2021 (two years). After obtaining approval from the institutional research and ethics committee of the hospital (Ref No E/MD/173/1/MS/III/DNB dated 27.9.19), 40 adults aged between 18 and 80 years, classified as ASA class I, II, and III, undergoing elective uncomplicated unilateral direct or indirect inguinal hernia repair were enrolled in the study after obtaining written consent.

**Inclusion criteria:** Both complete and incomplete types of indirect inguinal hernia were included in the study.

**Exclusion criteria:** Patient refusal, allergy to local anaesthetics or any included medications, recurrent, bilateral, irreducible, incarcerated, or large scrotal hernias, severe liver, renal, or cardiovascular diseases, coagulopathy, obesity (Body Mass Index >30 kg/m<sup>2</sup>), infection at the site of injection, psychiatric disorders or neurological diseases, and severe deformities of the spinal column, such as severe kyphoscoliosis, arthritis, and previous lumbar fusion surgeries were excluded from the study.

**Sample size calculation:** The sample size was calculated with the help of study by Fekry DM et al., [11]. The calculated sample size was 19 patients per study group. To account for possible dropouts, 20 patients per group were included. Patients were randomised and divided into two groups: Group A received SAB, and Group B received ultrasound-guided HB only. The allocation was performed by the author using a computerised random sequence generator without blinding due to the obvious differences between the two types of anaesthesia, and a CONSORT flowchart was followed for the study [Table/Fig-1].

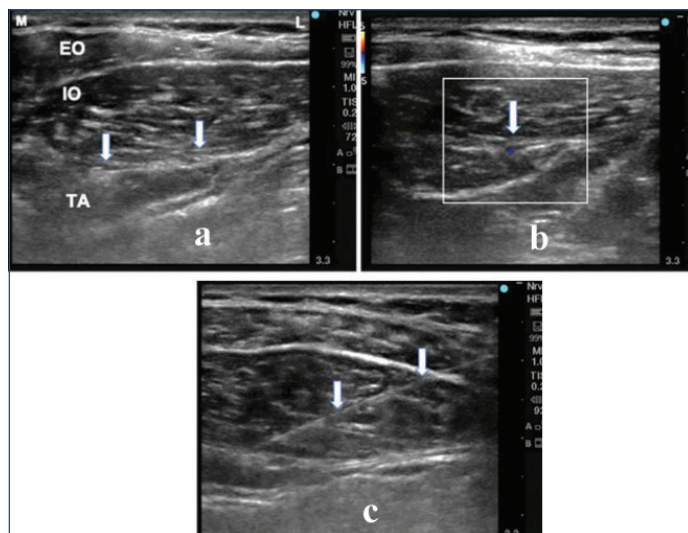


[Table/Fig-1]: The study's CONSORT flowchart.

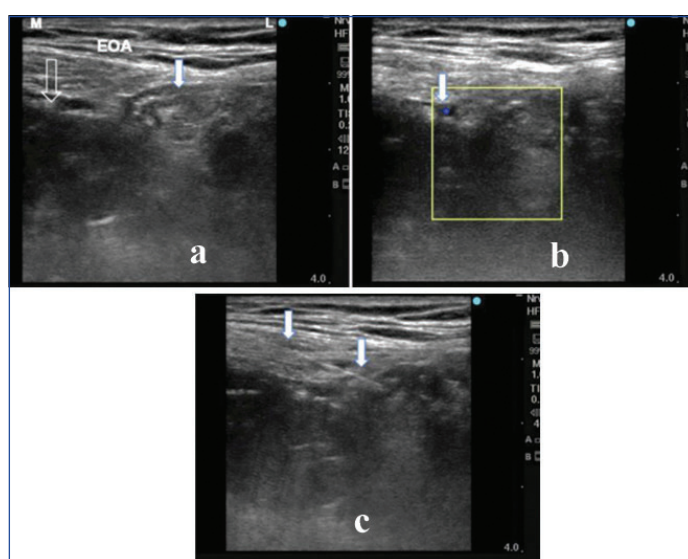
## Study Procedure

Preoperative anaesthetic assessment, including history, physical examination, and routine investigations, was conducted. Intravenous access was secured, and the patients were connected to a multiparameter monitor. Patients in group A were preloaded with Ringer's Lactate at a dose of 10 mL/kg body weight. Subsequently, SAB was administered with 3.5 cc of 0.5% hyperbaric bupivacaine at the L3-L4 space using a 25 G Quincke spinal needle through a midline approach [12]. Patients in Group B were given an IIN-IHN nerve block using an ultrasound machine, Sonosite Edge II (Fujifilm Sonosite, India), equipped with a high-frequency probe (13-6 MHz, linear probe). The probe was placed obliquely at the anterior superior iliac spine along the line connecting the umbilicus and the anterior superior iliac spine. After visualising the nerves in the fascial split between the internal oblique and the transversus abdominis [Table/Fig-2], local infiltration with 2% plain lignocaine at the site of needle entry was performed. An 80 mm 22 G needle was then used in the in-plane approach to reach the nerves. After negative aspiration, 15 mL of 0.325% isobaric bupivacaine was deposited between the transversus abdominis and the internal oblique until the nerves were surrounded by the drug.

For the genital branch of the genitofemoral nerve block, the inferior epigastric vessels were localised under the rectus sheath, and the probe was subsequently moved caudally to the point where the inferior epigastric artery joins the external iliac artery. At this level, the probe was moved medially toward the pubis and tilted obliquely, perpendicular to the inguinal ligament, to locate the spermatic cord. Another approach would be to follow the femoral artery cranially until it enters the external iliac artery, then move the probe medially at this level toward the pubis and tilt it obliquely to locate the spermatic cord [5-6]. Once the spermatic cord was identified [Table/Fig-3], an 80 mm 22 G block needle was introduced from the lateral side using the in-plane approach. Once the needle tip was adjacent to the spermatic cord, 5 mL of 0.325% isobaric bupivacaine was deposited after aspiration, and an additional 5 mL was infiltrated inside the cord. If the patient felt uncomfortable during surgery, the surgeon was asked to infiltrate the spermatic cord with 5-10 mL of 1% lignocaine.



[Table/Fig-2]: a) External Oblique (EO) muscle, Internal Oblique (IO) muscle, and Transverse Abdominis (TA) muscle. Ilioinguinal nerve and Iliohypogastric nerve in TA plane (arrow); b) Dorsal circumflex artery in colour Doppler in the same plane (arrow); c) Precise needle placement (arrow).



[Table/Fig-3]: a) Scan at lateral to pubic tubercle. External Oblique Aponeurosis (EOA), Pubic tubercle's acoustic shadow (hollow arrow), and spermatic cord (solid arrow); b) Testicular vessels in colour Doppler (arrow); c) Needle placement near spermatic cord (arrow).

Patients were considered to have adequate anaesthesia when there was a complete loss of sensation to pinprick at the operation site. The time of onset of anaesthesia was recorded from the completion of the drug injection until the patient did not feel pinprick at the incision site. Intravenous midazolam 1 mg was administered to all patients. Supplemental analgesia was provided in the form of intravenous fentanyl 1 µg/kg when the Visual Analogue Scale (VAS) score was >3. Intravenous propofol was administered up to 1 mg/kg if any discomfort or pain persisted during surgery in any of the patients. If the requirement exceeded 1 mg/kg body weight, standard general anaesthesia was used, and this was noted as a failed block. Additionally, if analgesia to pinprick was not achieved, it was also considered a block failure.

The total duration of postoperative analgesia was defined as the time interval from the end of surgery until the VAS score exceeded 3. The duration of ambulation was defined as the time interval from the end of surgery until the patient started walking without support. Both groups were compared based on demographics, adequacy of anaesthesia, duration of anaesthesia, haemodynamic and respiratory changes, patient and surgeon satisfaction, propofol requirement, failure rate, and adverse effects. Patient satisfaction was assessed using a 5-point scale: 1-Very unsatisfied; 2-Satisfied; 3-Somewhat satisfied; 4-Satisfied; 5-Very

satisfied. Surgeon satisfaction was assessed using a 3-point scale: 1-Moderate; 2-Good; 3-Excellent [13].

## STATISTICAL ANALYSIS

The analysis was conducted using IBM® Statistical Package for the Social Sciences (SPSS) Statistics (version 22.0). All the data were collected, tabulated, and expressed as median/mean±standard deviation. Appropriate statistical analyses were conducted. The Analysis of Variance (ANOVA) test was applied for normally distributed quantitative data, such as demographic data, surgery duration, duration and onset of the block, and total propofol consumption. The Student's t-test was applied for normally distributed quantitative variables, like blood pressures and heart rate. The Mann-Whitney test was applied for abnormally distributed quantitative data, like ambulation time and patients' and surgeons' satisfaction. Any adverse effects, such as nausea, vomiting, bradycardia, hypotension, postoperative urinary retention, etc., were noted and analysed. A p-value <0.05 was considered to be statistically significant.

## RESULTS

There was no statistically significant difference between the two study groups in terms of age, gender, Body Mass Index (BMI), ASA scores, type of hernia, and duration of surgery [Table/Fig-4]. Group A was associated with more stable systolic and diastolic blood pressure throughout the procedure, and this was statistically significant when compared to the subarachnoid group, which experienced a fall at 30, 40, 50, 60, 70, 80, and 90 minutes [Table/Fig-5]. The respiratory rate was stable throughout the procedure in both groups, without any statistically significant difference between them.

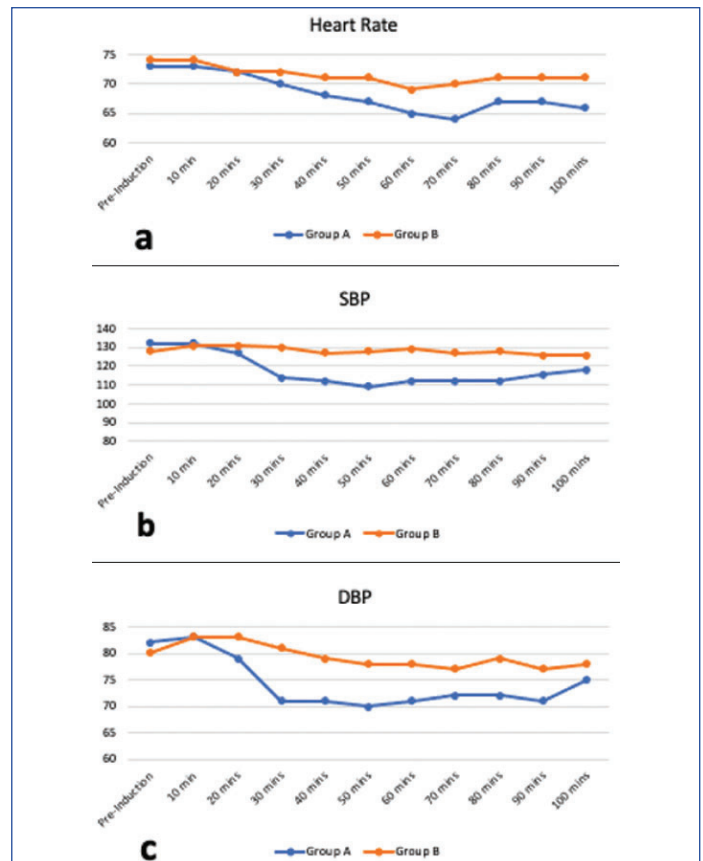| Patient characteristic               | Patient group |             | Analysis of variance test p-value |
|--------------------------------------|---------------|-------------|-----------------------------------|
|                                      | Group A       | Group B     |                                   |
| Age in years, Median (Range)         | 56 (33-68)    | 50 (26-76)  | 0.108                             |
| Gender, M: F                         | 20:0          | 20:0        | -                                 |
| Body Mass Index (kg/m <sup>2</sup> ) | 24 (20-28)    | 25 (20-38)  | 0.413                             |
| <b>ASA score:</b>                    |               |             |                                   |
| ASA I/II/III                         | 6/11/3        | 5/10/5      | 0.727                             |
| <b>Type of hernia:</b>               |               |             |                                   |
| Complete                             | 7             | 9           | 0.355                             |
| Incomplete                           | 13            | 11          |                                   |
| Duration of surgery (minutes)        | 100 (60-170)  | 95 (55-160) | 0.55                              |

[Table/Fig-4]: Patients' demographic profiles and characteristics.

The median time taken to perform the subarachnoid block was 11 (5-22) minutes, while for the ultrasound-guided HB group, it was 41 (27-70) minutes. The difference was statistically significant, with a p-value=0.002. The median time to onset of surgical anaesthesia after SAB was 5 (3-10) minutes, whereas for the ultrasound-guided HB group, it was 30 (15-75) minutes. This difference was statistically significant, with a p-value=0.003. The duration of analgesia was significantly longer in the ultrasound-guided HB group, with a median of 8 (2-11) hours compared to 5 (3-7) hours in the subarachnoid group, yielding a p-value=0.002. The failure rate was significantly higher in the ultrasound-guided HB group (20%, p-value=0.05). The requirement for supplementary Propofol was higher in the ultrasound-guided HB group (45% vs. 0%, p-value=0.001), with a median requirement of 27 (0-150) mg, while none was required at all in group B [Table/Fig-6].

Dermatome levels were studied in both groups. In the subarachnoid group, the sensory level was attained at T6 in 40% of patients and at T8 in 60%. In the ultrasound-guided HB group, the sensory level was attained at T10 in 65% and T11 in 35%.

Complications related to the procedure were significantly higher in the subarachnoid group (55% vs. 10%, p-value of 0.003). Nausea



[Table/Fig-5]: Chart showing the comparison of haemodynamic data between both groups. a) Heart Rate; b) Systolic blood pressure; c) Diastolic blood pressure.

| Characteristic                                       | Patient group |            | Analysis of variance test p-value |
|--|---------------|------------|-----------------------------------|
|  | Group A       | Group B    |                                   |
| Time taken to perform block median (Range) (minutes) | 11 (5-22)     | 41 (27-70) | 0.002                             |
| Onset of anaesthesia median (Range) (minutes)        | 5 (3-10)      | 30 (15-75) | 0.003                             |
| Duration of analgesia median (Range) (hrs)           | 5 (3-7)       | 8 (2-11)   | 0.002                             |
| Failure rate (%)                                     | 0             | 20         | 0.05                              |
| Supplement requirement (%)                           | 0             | 45         | 0.001                             |
| Propofol requirement median (Range) (mg)             | 0             | 27 (0-150) | 0.011                             |

[Table/Fig-6]: Characteristics outcomes of the blocks in study groups.

and vomiting were comparable between the groups, whereas bradycardia and urinary retention occurred only in the subarachnoid group. The incidence of urinary retention was 25% (n=5), and bradycardia occurred in 20% (n=4) [Table/Fig-7].

| Complications       | Patient group |         | Mann Whitney test p-value |
|---------------------|---------------|---------|---------------------------|
|                     | Group A       | Group B |                           |
| Nausea and vomiting | 2             | 2       | 0.7                       |
| Bradycardia         | 4             | 0       | 0.005                     |
| Urinary retention   | 5             | 0       | 0.005                     |

[Table/Fig-7]: Comparison of complications between study groups.

Surgeon and patient satisfaction were significantly better in the subarachnoid group. Surgeon satisfaction was graded as excellent, and patient satisfaction as very satisfied in all patients in the subarachnoid group. In contrast, in the ultrasound-guided HB group, surgeon satisfaction was graded as moderate in 75% of patients, and patient satisfaction was rated as satisfied in 80% of patients (p-values=0.004 and 0.003, respectively). The median ambulation time was shorter in the ultrasound group, at 5.5 hours compared to 11.5 hours in the subarachnoid group (p-value <0.001) [Table/Fig-8].

|                                      | Patient group |               | Mann-Whitney test p-value |
|--------------------------------------|---------------|---------------|---------------------------|
|                                      | Group A       | Group B       |                           |
| Surgeon satisfaction                 |               |               |                           |
| Moderate                             | 0             | 4             | 0.004                     |
| Good                                 | 5             | 11            |                           |
| Excellent                            | 15            | 5             |                           |
| Patient satisfaction                 |               |               |                           |
| Somewhat satisfied                   | 0             | 4             | 0.003                     |
| Satisfied                            | 0             | 16            |                           |
| Very satisfied                       | 20            | 0             |                           |
| Unsatisfied                          | 0             | 0             |                           |
| Very unsatisfied                     | 0             | 0             | <0.001                    |
| Time to Ambulate, Median (Range) Hrs | 11.5 (7.4-18) | 5.5 (3.4-8.2) |                           |

[Table/Fig-8]: Patient and surgeon satisfaction and the time to ambulate between study groups.

DISCUSSION

There has been significant inertia among anaesthesiologists in adopting the inguinal field block as the preferred method for uncomplicated unilateral hernia repair, despite its constant recommendation by international guidelines [14]. With the inclusion of ultrasound in the anaesthesia armamentarium, there has been a resurgence of ultrasound-guided nerve blocks in hernia repair.

In this study, there was a significant difference in mean arterial pressure, systolic blood pressure, and diastolic blood pressure between the study groups. The ultrasound-guided HB was associated with minimal changes in blood pressure during the procedure. However, there was no statistical difference in terms of heart rate or respiratory rate between the groups. This may be explained by the preganglionic sympathetic blockade induced by the subarachnoid block, resulting in peripheral venous pooling and decreased preload. It is observed that ultrasound-guided nerve block can be an effective alternative for patients who may not tolerate the haemodynamic derangements associated with central neuraxial blockade. The results of the present study are consistent with those of Chhatrapati S et al., regarding Mean Arterial Pressure (MAP), heart rate, and respiratory rate [15].

The time taken to perform spinal anaesthesia was significantly less, but the median time to perform the ultrasound-guided block may decrease with more experience. The onset of analgesia in the present study was significantly longer in the ultrasound-guided group. The delay may be explained by the time required for the local anaesthetic to spread. In comparative studies by different authors the duration to onset of the sensory block after ilioinguinal and iliohypogastric nerve blocks for inguinal hernia repair was significantly longer when compared to SAB. These results are consistent with the present findings; however, in these studies, the duration to onset ranged from 6 to 19 minutes. The faster onset of analgesia in those studies may be explained by the different drug combinations and concentrations (0.5% bupivacaine and 2% lignocaine) used, as compared to the 0.325% bupivacaine used in the present study [14-17].

In this study, the duration of analgesia, defined as the time to first rescue analgesia, was significantly longer in the ultrasound-guided HB group (median duration of 8 hours vs. 5 hours). In agreement with present study, Khedkar SM et al., found the duration of analgesia to be 7.22±0.97 hours in the ultrasound-guided technique of HB [16]. Chhatrapati S et al., reported that the duration of analgesia was 3.87±0.482 hours in the spinal group and 5.16±0.45 hours in the HB group, with the result being statistically significant at a p-value of <0.05 [15]. Fekry DM et al., found that the duration of sensory block was 3.71±0.64 hours in the spinal group and 4.49±0.47 hours in the ultrasound-guided group. Thus,

the demand for the first rescue analgesia was significantly earlier in the spinal group (p-value <0.001) [11].

In disagreement with present study, Yilmazlar A et al., showed that the time to the first dose of rescue analgesia postoperatively was 3.30±0.2 hours in the spinal anaesthesia group and 2.7±0.13 hours in the ilioinguinal and iliohypogastric nerve block group [17].

In this study, propofol was not required intraoperatively in group A, while it was necessary in group B, which was in agreement with Song D et al., who found that the total dosage of propofol used intraoperatively in the SAB group was significantly lower than that in the ilioinguinal and iliohypogastric nerve block group. This may be explained by the persistence of pressure and traction sensations on deeper tissues after local anaesthesia blocks, which may require intravenous sedation [18]. Propofol, with its rapid elimination and rapid redistribution, is the closest to an ideal agent for sedation during regional anaesthesia. In a review by Höhener D et al., propofol was mentioned as an ideal agent for sedation required to overcome the discomfort associated with regional anaesthesia [19]. Although the requirement for propofol may decrease with the infiltration of the genitofemoral nerve, supplemental propofol is still safe and may be used as an adjunct without any major adverse outcomes [20]. Present study failure rate of 20% was higher than the 10% reported by Chhatrapati S et al., [15]. This higher failure rate may be related to the learning curve associated with the procedure, as there was only one failure in the second half of the study.

Results of patient satisfaction in this study are inconsistent with those of both Fekry DM et al., and Bang YS et al., who showed that patient satisfaction in the recovery room was not significantly different between the two groups. In the present study and in the study by Fekry DM et al., surgeons were significantly more satisfied in the subarachnoid group. However, Bang YS et al., showed that surgeon satisfaction was significantly higher in the IHNB group [11,20].

Consistent with the present study, Chhatrapati S et al., Hiquemat and Ahmad H, and Pramod et al., found significantly less time to ambulation in the ilioinguinal and iliohypogastric block group (119.90±26.98 mins) compared to the SAB group (291.25±32.24 mins) [15,21,22].

In the present study, the incidence of nausea and vomiting was comparable between the groups, whereas bradycardia (25%) and urinary retention (20%) occurred only in Group B. The complications related to the procedure are in agreement with the studies by Chhatrapati S et al., and Hiquemat N and Ahmad H, who showed a statistically insignificant difference in the incidence of nausea and vomiting. In these studies, the incidence of urinary retention in the subarachnoid group ranged from 10% to 20%, which was comparable to present study findings [15,21].

Limitation(s)

The learning curve bias in the initial part of the study may be responsible for the higher failure rate of the ultrasound-guided block.

CONCLUSION(S)

The ultrasound-guided HB may be considered an effective alternative to the subarachnoid block for unilateral hernia repair in terms of haemodynamic stability, postoperative analgesia, fewer complications, and early ambulation. Ultrasound-guided HB is preferable for patients with cardiovascular co-morbidities who may not tolerate haemodynamic changes. Postoperative analgesia is better with the ultrasound-guided block. The addition of the genitofemoral nerve block may decrease the need for supplemental propofol. Early ambulation and minimal complications make ultrasound-guided HB the ideal mode of anaesthesia for day-care surgery.

REFERENCES

[1] Amado WJ. Anaesthesia for hernia surgery. Surg Clin North Am. 1993;73:427-38.

- [2] Young DV. Comparison of local, spinal, and general anaesthesia for inguinal herniorrhaphy. *Am J Surg.* 1987;153:560-63.
- [3] Kulacoglu H. Current options in inguinal hernia repair in adult patients. *Hippokratia.* 2011;15:223-31.
- [4] Kehlet H, White PF. Optimizing anaesthesia for inguinal herniorrhaphy: General, regional, or local anaesthesia? *Anaesth Analg.* 2001;93:1367-69.
- [5] Terkawi AS, Romdhane K. Ultrasoundguided pulsed radiofrequency ablation of the genital branch of the genitofemoral nerve for treatment of intractable orchalgia. *Saudi J Anaesth.* 2014;8:294-98.
- [6] Frassanito L, Zanfini BZ, Pitoni S, Gemini P, Del Vicario M, Catarci S, et al. Ultrasound-guided genitofemoral nerve block for inguinal hernia repair in the male adult: A randomized controlled pilot study. *Minerva Anesthesiol.* 2018;84(2):189-95.
- [7] Wang Y, Wu T, Terry MJ, Eldrige JS, Tong Q, Erwin PJ, et al. Improved perioperative analgesia with ultrasound-guided ilioinguinal/iliohypogastric nerve or transversus abdominis plane block for open inguinal surgery: A systematic review and meta-analysis of randomized controlled trials. *J Phys Ther Sci.* 2016;28(3):1055-60.
- [8] Eichenberger U, Greher M, Kirchmair L, Curatolo M, Moriggi B. Ultrasound guided blocks of the ilioinguinal and iliohypogastric nerve: Accuracy of a selective new technique confirmed by anatomical dissection. *Br J Anaesth.* 2006;97:238-43.
- [9] Weintraud M, Lundblad M, Kettner SC, Willschke H, Kapral S, Lönnqvist PA, et al. Ultrasound versus landmark-based technique for ilioinguinal iliohypogastric nerve blockade in children: The implications on plasma levels of ropivacaine. *Anaesth Analg.* 2009;108:1488-92.
- [10] Abrahams MS, Aziz MF, Fu RF, Horn JL. Ultrasound guidance compared with electrical neurostimulation for peripheral nerve block: A systematic review and meta analysis of randomized controlled trials. *Br J Anaesth.* 2009;102:408-17.
- [11] Fekry DM, Megahed NA, EL-Lakany MH, Yakout MM. Ultrasound-guided ilioinguinal, iliohypogastric, and genitofemoral nerve block versus spinal subarachnoid blockade for inguinal hernia repair. *Res Open Anaesth Intensive Care.* 2017;4:29-34.
- [12] Dongare DH, Dongare HC. Comparison of ilio-inguinal ilio-hypogastric nerve block versus spinal anaesthesia for hernia repair as day care surgery. *Perspectives in Med Res.* 2014;2:07-12.
- [13] Onyekwulu FA, Nwosu AD. Measuring patient satisfaction with anaesthesia care in Enugu: A preliminary study. *Int J Med Health Development.* 2009;14:55-59.
- [14] Simons MP, Aufenacker T, Bay-Nielsen M, Bouillot JL, Campanelli G, Conze J, et al. European Hernia Society guidelines on the treatment of inguinal hernia in adult patients. *Hernia.* 2009;13(4):343-403.
- [15] Chhatrapati S, Sahu A, Patil S. Comparative evaluation of ilioinguinal/iliohypogastric nerve block with spinal anaesthesia for unilateral open inguinal hernia repair. *Int J Contemp Med Res.* 2016;3:1177-81.
- [16] Khedkar SM, Bhalerao PM, Yemul-Golhar SR, Kelkar KV. Ultrasound-guided ilioinguinal and iliohypogastric nerve block, a comparison with the conventional technique. An observational study. *Saudi J Anaesth.* 2015;9:293-97.
- [17] Yilmazlar A, Bilgel H, Donmez C, Guney A, Yilmazlar T, Tokat O. Comparison of ilioinguinal-iliohypogastric nerve block versus spinal anaesthesia for inguinal herniorrhaphy. *Southern Med J.* 2006;99:48-52.
- [18] Song D, Greilich NB, White PF, Watcha MF, Tongier WK. Recovery profiles and costs of anaesthesia for outpatient unilateral inguinal herniorrhaphy. *Anaesth Analg.* 2000;91:876-81.
- [19] Höhener D, Blumenthal S, Borgeat A. Sedation and regional anaesthesia in the adult patient. *Br J Anaesth.* 2008;100:08-16.
- [20] Bang YS, Park C, Lee SY, Kim M, Lee J, Lee T. Comparison between monitored anaesthesia care with remifentanyl under ilioinguinal hypogastric nerve block and spinal anaesthesia for herniorrhaphy. *Korean J Anaesthesiol.* 2013;64:414-19.
- [21] Hiquemat N, Ahmad H. A comparative study of hernioplasty done under local and spinal anaesthesia in a tertiary care centre. *IOSR J Dent Med Sci.* 2017;16:18-24.
- [22] Pramod K, Bindra TK, Kumar A, Shankar U. Comparison of Ilioinguinal Iliohypogastric nerve block with spinal anaesthesia for inguinal hernia repair. *Int J Med Health Res.* 2019;5:37-42.

**PARTICULARS OF CONTRIBUTORS:**

1. Senior Consultant, Department of Anaesthesiology, Jagjivan Ram Railway Hospital, Mumbai, Maharashtra, India.
2. Ex Resident, Department of Anaesthesiology, Jagjivan Ram Railway Hospital, Mumbai, Maharashtra, India.
3. Senior Consultant, Department of Anaesthesiology, Jagjivan Ram Railway Hospital, Mumbai, Maharashtra, India.
4. Senior Consultant, Department of Anaesthesiology, Jagjivan Ram Railway Hospital, Mumbai, Maharashtra, India.

**NAME, ADDRESS, E-MAIL ID OF THE CORRESPONDING AUTHOR:**

Dr. Dinesh Kumar Sahu,  
D-7, Nirmal Park Railway Colony, Byculia, Mumbai-400027, Maharashtra, India.  
E-mail: drdksahujrh@gmail.com

**PLAGIARISM CHECKING METHODS:** [Jain H et al.]

- Plagiarism X-checker: Jul 15, 2024
- Manual Googling: Sep 14, 2024
- iThenticate Software: Sep 16, 2024 (13%)

**ETYMOLOGY:** Author Origin**EMENDATIONS:** 8**AUTHOR DECLARATION:**

- Financial or Other Competing Interests: None
- Was Ethics Committee Approval obtained for this study? Yes
- Was informed consent obtained from the subjects involved in the study? Yes
- For any images presented appropriate consent has been obtained from the subjects. NA

Date of Submission: **Jul 13, 2024**  
Date of Peer Review: **Aug 12, 2024**  
Date of Acceptance: **Sep 20, 2024**  
Date of Publishing: **Dec 01, 2024**